

RECONSTRUCTION OF THE BURNT NOSE USING A CARVED FLAP IN FOUR CASES

RECONSTRUCTION DU NEZ BRÛLÉ PAR UN LAMBEAU SCULPTANT: À PROPOS DE QUATRE CAS

Mimoun M., Almadani O., Boccara D., Chaouat M., Al Saud N., Serror K., Haddad J.✉

Department of Burn Care, Saint Louis Hospital, Paris, France

SUMMARY. Techniques for reconstructing nasal defects in burns are very limited because the surrounding scar tissue makes it difficult to use local flaps. The authors report their experience using the Converse scalping flap harvested from scarred skin, placed as a mass on the nasal area, then secondarily carved to shape the nose and covered by a skin graft. This is a retrospective study of 4 patients, 3 men and 1 woman, with an average age of 45 years, who were operated on between 1994 and 2013 using this technique for postburn nasal reconstruction. Patients had 45% burns on average. The flap was weaned from its donor site at the third week and the frontalis donor area grafted. Several months later, the flap was sculpted from the outside to the inside in the three dimensions, removing the scarred epidermal areas to restore the aesthetic units of the nose, which were grafted using a full thickness skin graft. The final aesthetic result of the nasal reconstruction was evaluated by the patient and the surgical team. The four nasal reconstructions were carried out to completion. Three were rated as 'very good' (75%) and one was rated as 'good' (25%). The Converse flap modification, referred to as the "carved flap", to reconstruct the burned nose is a reliable technique, possible on a scarred forehead with no additional donor site morbidity.

Keywords: burnt nose, skin graft, carved flap, reconstruction of the nose

RÉSUMÉ. Les techniques de reconstruction nasale après brûlure sont limitées. En effet, la peau cicatricielle environnante rend difficile l'utilisation de lambeaux locaux. Les auteurs rapportent leur expérience avec le lambeau scalpant de Converse prélevé en peau cicatricielle, placé en bloc sur la région nasale puis secondairement sculpté pour donner sa forme au nez et greffé. Il s'agit d'une étude rétrospective sur quatre cas, 3 hommes et 1 femme, d'un âge moyen de 45 ans, opéré entre 1994 et 2013, en utilisant cette technique de reconstruction nasale après brûlure. Les patients étaient brûlés en moyenne à 45% de la surface corporelle. Le lambeau a été sevré du site donneur à trois semaines et la perte de substance au niveau du front a été greffée. Plusieurs mois plus tard, le lambeau a été sculpté de dehors en dedans dans les trois dimensions, la peau cicatricielle a été désépidermée sur l'unité esthétique du nez qui a été greffée en peau totale. Le résultat esthétique final de cette reconstruction nasale a été évaluée à la fois par le patient et par l'équipe chirurgicale. Les quatre reconstructions nasales ont été menées à terme. Elles ont été cotées comme très bon résultat dans 75% des cas et comme bon résultat dans 25% des cas. Ce lambeau de Converse modifié, appelé « lambeau sculpté », est une technique fiable pour reconstruire un nez, possible sur un front cicatriciel et sans morbidité additionnelle au site donneur.

Mots-clés : brûlure du nez, greffe de peau, lambeau sculpté, reconstruction du nez

✉Corresponding author: Dr Jonathan Haddad, Service de chirurgie plastique esthétique et reconstructrice unités de traitement des grands brûlés, Hôpital Saint Louis, 1 avenue Claude Vellefaux, 75010 Paris, France. Email: jonathanhaddad26@hotmail.com
Manuscript: submitted 22/09/2018, accepted 26/09/2018

Introduction

The nasal pyramid is an essential component of facial identity.¹ Due to its projection, it is the first structure to be affected in facial burns. This has important aesthetic, functional and social implications for the patient.

Scarring in burns inevitably leads to a retraction of the tip of the nose, with elevation of the nasal margin and widening of the nasal orifices.²

In Europe, nasal reconstruction began in the 15th century in Sicily with the Brancas, who first used cheek flaps and then arm flaps.³ In 1597, Gaspare Tagliacozzi improved the technique and published a book entirely devoted to this subject ('De curtorum chirurgia par instronem').^{4,5}

During British colonial times, an ancient Indian method of nasal reconstruction (Sushruta, 6BC) was reported by Carpie in the Gentleman's Magazine (British monthly magazine) - a precursor to the current technique of the oblique frontalis flap.⁶

The free flaps that were subsequently used for rhinopoiesis gave a significant donor site morbidity and rarely resulted in an acceptable aesthetic outcome.^{7,8} This was due to a mere two-dimensional approach that failed to constitute the essential projection of the nasal pyramid.¹

Reconstruction of the nasal wings is still particularly challenging due to their anatomical constitution in 3 distinct planes (cutaneous, cartilaginous and mucosa) and their role in nasal ventilation to be recovered.

The techniques described in the literature for nose reconstruction in burns are most often complex, using primarily locoregional flaps or, less frequently, distant flaps² with or without expansion,⁹ free flaps¹⁰ or even prefabricated flaps.^{11,12}

Panfacial burns result in the destruction of donor areas for local and regional flaps used for the reconstruction of the nose.

This specificity of poorly exploited locoregional donor sites led us to consider a novel solution for the reconstruction of the burned nose, most of the conventional techniques not being feasible. It consists of the use of forehead scar tissue harvested as the Converse flap and placed as a shapeless mass on the nasal area, which is secondarily carved and then

grafted. This alternative has never been described in the literature. It restores the aesthetic units of the nose in all dimensions. We called it the "carved flap".

We present our experience of four cases of rhinopoiesis using the "carved flap".

Methods

We present a retrospective case series of four patients who had a "carved flap" for nasal reconstruction between 1994 and 2013. Individual patient files were reviewed and demographic information, lesions at presentation, surgical details, postoperative assessments and complications were recorded. The patients continue to have ongoing multi-disciplinary follow-up at the Burn Centre in the Hôpital Saint Louis. Pre- and post-op pictures are presented for the readers' judgement of the aesthetic result. The authors also present their impression on the aesthetic outcome.

Results

All four patients presented with an amputation of the tip of the nose and bilateral loss of the alar subunits. All reconstructions were carried out to completion. Nasal amputation was secondary to immolation burn (n = 2), gas burner explosion (n = 1), and home fire (n = 1). They were three men and one woman. The mean age of the patients at the time of reconstruction was 45 years (36-53 years). One patient had a psychiatric disorder, and another was diabetic. Four patients had scarred foreheads, and one of them had a scarred scalp (*Table I*). All patients had scarred auricles bilaterally.

Table I - Patient demographics and lesions at presentation

	Age	Sex	TBSA* burned	Forehead	Scalp
Patient A	36	M	42%	Scarred	Intact
Patient B	41	M	40%	Scarred	Scarred
Patient C	53	M	90%	Scarred	Intact
Patient D	48	F	30%	Scarred	Intact

*TBSA: Total Body Surface Area

Surgical procedure

This therapeutic strategy was principally guided by the presenting lesions of the subjects. Its evolution was stepwise, without insight of the end result. The forehead was selected as a donor area for autologous tissue replacement, as the use of local or free flaps was precluded by the burn lesions. The tissue mass was to be brought to the nose by means of a Converse flap. Due to the scarred forehead, an elevated risk for ischemic failure of the flap was taken into account. The variables considered to secure vascularity were staging the elevation and the plane of dissection of the flap. The multi-step character of the reconstruction was foreseen as the flap was to be separated after 2-3 weeks. Carving the flap and covering with a skin graft was performed in a further operation. The reconstruction steps were as follows:

Step one: staged elevation (Fig. 1). The design marking out the flap on the frontalis area was greater than the defect to be reconstructed. In three cases, we opted for a staged elevation to safeguard vascular supply. Only the frontal part of the flap was raised in the subcutaneous plane and then sutured back onto its original site. The surgical delay for the following operation was 17 days (10-30 days).

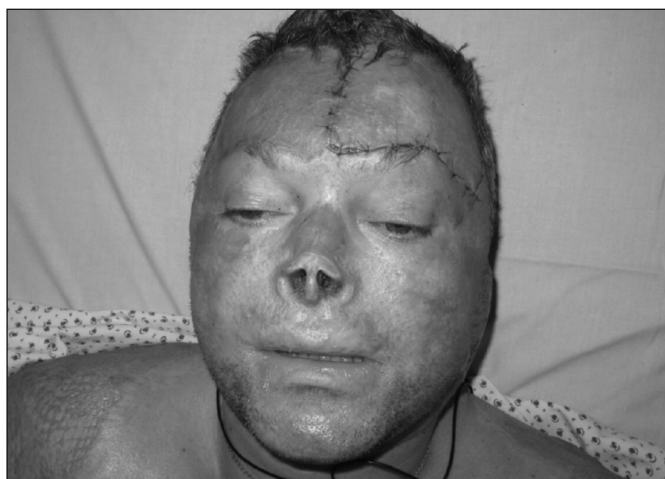

Fig. 1 - Patient A: Post-op picture of staged elevation of the Converse flap

Step two: raising the Converse flap (Fig. 2). The Converse flap was harvested according to the standard technique.¹³⁻¹⁵ The flap of patient B was elevated directly in the sub-muscular plane in the frontal part. In the three patients who had prior staged elevation, the frontal part was raised again in

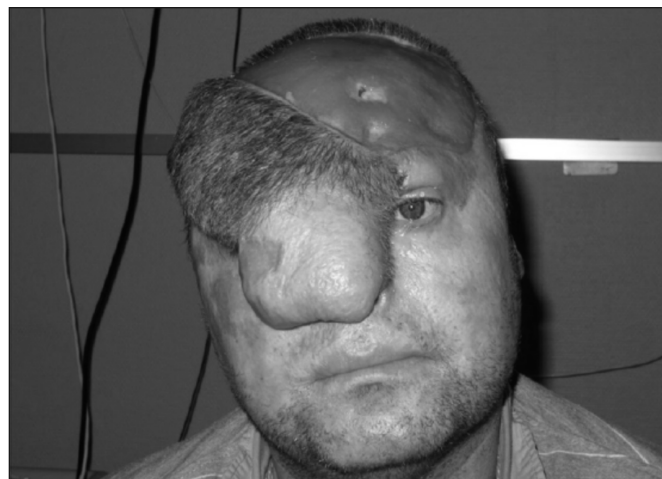

Fig. 2 - Patient A: Post-op picture with the Converse flap placed at the level of the nose.

the subcutaneous plane. At the level of the scalp, undermining proceeded in the subgaleal plane. The very large arc of rotation of the flap allowed it to reach the middle and lower parts of the face easily. The stripped area of the scalp was protected by vaseline dressing fixed with a tie-over.

Step three: division of the Converse flap (Fig. 3). The flap was divided from its pedicle at day 19 (13-21 days). The frontalis donor area was covered by a skin graft at the same time.

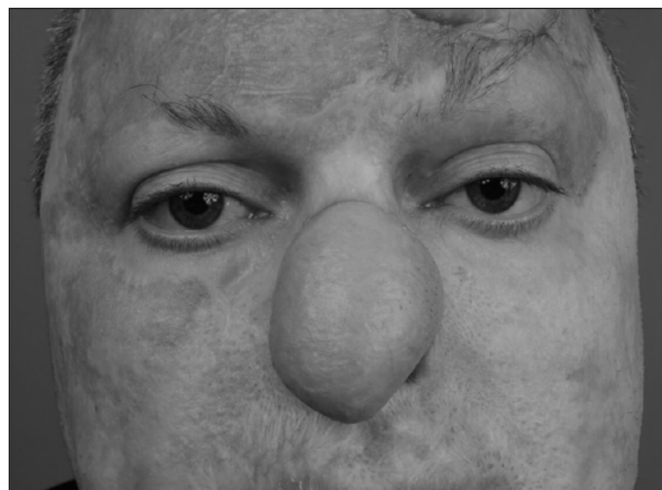

Fig. 3 - Patient A: Post-op picture with the divided flap resulting in an intact soft tissue mass in nose area.

Step four: carving and graft (Fig. 4). Several months later, the flap was carved by directly removing the scarred epidermis until a satisfactory three-dimensional form of the nose was obtained. The carving is done with a sharp scalpel in a similar way to the cold shaving of rhinophyma,¹⁶ to re-

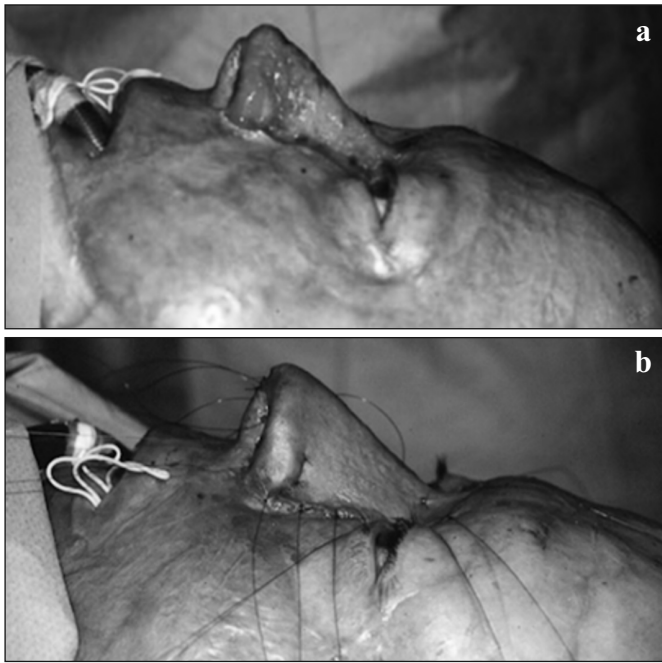


Fig. 4 - Patient C: Carving and skin graft; a) the flap was carved directly to obtain a satisfactory three-dimensional form with the anatomical entities of the nose, b) the sacrificed epidermis was replaced by a full-thickness skin graft.

define the aesthetic sub-units of the nose. A full thickness skin graft was then used for 3 out of the 4 cases, and a split thickness skin graft for one. The skin grafts applied during the sculpting stage were taken from an intact area: the abdomen, the scalp, the inner thigh and the ankle.

In total, nasal reconstruction was performed in four stages for three patients (prior autonomisation of the frontalis area) and in three stages for the remaining one (without autonomisation).

Cartilage reinforcement was not necessary: the block of fibrosis was sufficient to maintain the nasal form. Complementary procedures were needed for 2 patients: patient D had a remodelling of the nasal orifices and disinsertion of the columella before the harvesting and inset of the scalping flap. Patient A had a V-Y flap to correct the nasal orifice stenosis at the internal inferior border of the nostrils.

Complications

Patient D presented a partial dehiscence of the flap due to local infection in a bout of uncontrolled diabetes. This dehiscence was treated in a secondary procedure with no complications. Patient B, who had a psychological disorder, tampered with his graft prematurely and received a second skin graft due to

poor take of the first. There was no necrosis of the flap, even partially, in any of the cases.

Aesthetic outcome

The aesthetic outcome is presented in pre-op and post-op adjacent photos (Figs. 5,6,7). No pre-op

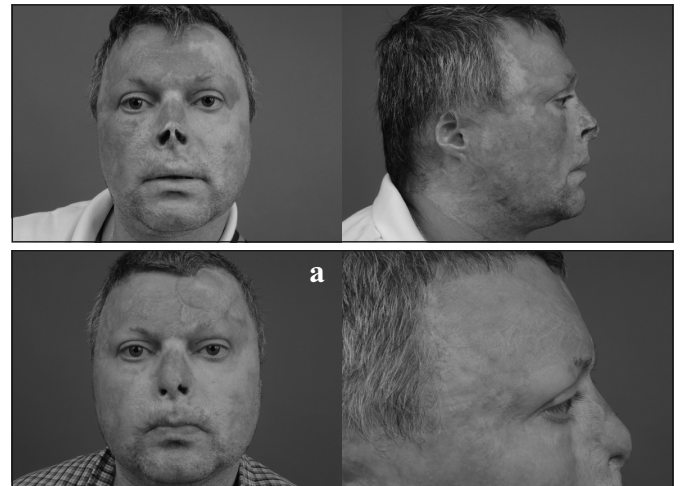

Fig. 5 - Patient A: Pre-op (top) and after completed reconstruction with a carved flap (bottom); a) front view, b) profile view.

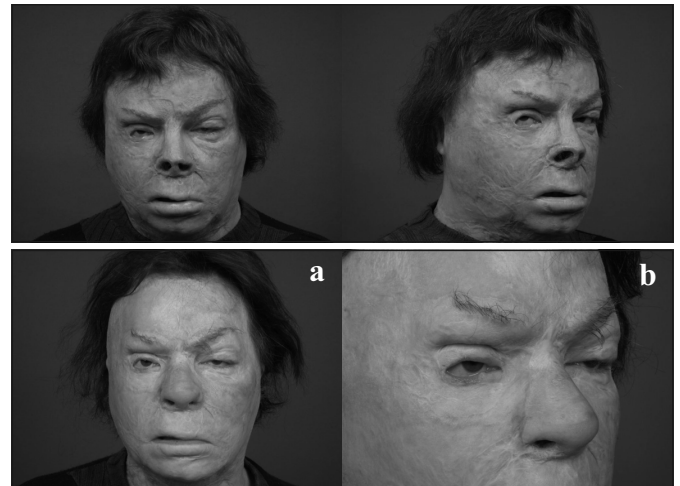

Fig. 6 - Patient B: Pre-op (top) and after completed reconstruction with a carved flap (bottom); a) front view, b) profile view.

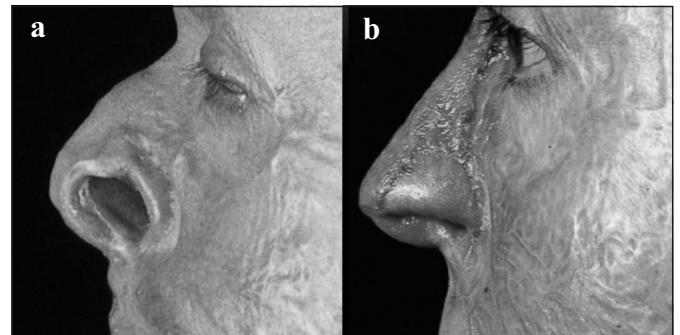


Fig. 7 - Patient C: Pre-op (a) and after completed reconstruction with a carved flap (b) in profile view.

medical photos of patient D were available. The authors judge the reconstruction to be very good for patients A, B and C, and good for patient D because of the poor scar healing and limited definition of the nasal contour. However, patient D judged the reconstruction sufficiently satisfactory not to warrant further intervention.

Discussion

According to Foyatier et al., rhinopoiesis is always first in the chronology of reconstruction of the burned face, because it is the one that will most improve facial physiognomy. Many techniques have been described, with none of them being totally satisfactory.^{9,11,17,18} In burn victims, poor skin quality, poor modelling (fibrosis) and precarious vascularization precludes many surgical reconstruction techniques, and scarred zones render local flaps difficult, with vascular and dissection problems, and limited arcs of rotation and modelling. The recipient vessels are not always reliable, which limits the use of free flaps in the burned. Panfacial burns require reconstruction of all the planes with mucosa, cartilage and skin. In the literature, the frontalis flap based on the supra-trochlear artery is widely used for extensive rhinopoiesis, but it is difficult to exploit in the burned.^{17,19,20}

Hataya et al.²¹ present a case of reconstruction of the ala in a burned patient with a pedicled island skin flap based on the infra-orbital vessels, requiring skin grafts on the ala of the nose and the donor area. This technique causes an enlarged appearance of the tip and ala.

The use of free flaps (radial forearm, anterolateral thigh, auricular flap) to reconstruct the wings of the nose seems to give very satisfactory aesthetic and functional results.^{18,22}

They are mainly indicated in trauma or post-tumour reconstructions. In the burned area, poor donor areas make harvesting very difficult. Frequent involvement of superficial temporal vessels, facial and helix vessels, and cartilage of the helix used for the cartilaginous graft render this technique impossible in the burned patient.

The transfer of a mass of tissue to another site to be subsequently carved and fashioned to the 3-dimensional desired shape constitutes the principle of the "carved flap". As the harvested tissue is thick (muscu-

locutaneous flap) and stiff (scarred tissue), it allowed only limited pliability, and the primary result was a shapeless mass, intended to be sculpted secondarily in the three dimensions of space.

This stiffness also renders the use of cartilaginous graft for additional support unnecessary.

A double distal plication of the cutaneous paddle (vertical plication on the median line and horizontal plication laterally) will redesign the columella and the contours of the nasal orifices. We thus reconstructed a well-shaped nose with all its aesthetic subunits as described by Burget (dorsum, tip, side walls, narrow wings, soft triangles and columella).²³

The absence of even partial necrosis in the various flaps indicates the vascular reliability of this technique. The partial dehiscence of one flap due to a local infection secondary to uncontrolled diabetes was treated with no particular problems. According to Barret, and as we have seen in our reconstructions, the skin flaps raised in the burnt zone cause no more complications than those raised in healthy areas.²⁴ A total or split thickness skin graft avoids the risk of tip scarring. We observed a skin graft failure following untimely tampering by the patient, without altering the final result of the reconstruction. Colour and texture matching must be taken into account in panfacial burns, and this is ensured in the carved flap by a good match between forehead skin and the nose. For a better aesthetic result, the skin graft must respect the aesthetic subunits of the nose.²⁵

Donor site morbidity is minimal. The use of the frontalis muscle does not detract from facial expression, because in these burned areas covered with rigid skin, the function is minimal. The disadvantage of the Converse scalping flap is the duration of treatment, with a partial limitation of the visual field for three weeks, causing discomfort for the patient. A preoperative psychological preparation of the patients, continued postoperatively, was very beneficial in our service. We sought to minimize the risk of necrosis of the Converse flap in burnt skin with either a staged elevation or by raising in the submuscular plane.

The four patients were satisfied with their care. The schedule of treatment, explained in consultation, was always well accepted by the patients and therefore does not appear to be an obstacle to this type of care.

Despite these good results, we believe that this tech-

nique requires the surgeon to have great expertise in rhinoplasty and burn surgery.

Conclusion

Reconstruction of the burned nose is particularly challenging due to the regular concomitant involvement of the locoregional donor and recipient areas in a pan-

facial burn. The technique of the “carved flap”, using scar tissue from the forehead, is particularly effectual for the burnt patient. The overall idea is to provide a soft tissue construct, which initially requires ‘carving’ for contour, and then resurfacing with a skin graft. This reliable and reproducible technique makes it possible to obtain a satisfactory aesthetic and functional result with minimal donor site sequelae, facilitating the social reintegration of the patient with a burnt face.

BIBLIOGRAPHY

- 1 Talmant J: Reconstruction du nez. Reconstruction partielle et totale - EM Premium [Internet, cited 2017 Dec 11].
- 2 Foyatier J-L: Traitement des séquelles de brûlures : brûlures de la face - EM Premium [Internet, cited 2017 Dec 11].
- 3 Mazzola IC, Mazzola RF: History of reconstructive rhinoplasty. *Facial Plast Surg*, 30(3): 227-36, 2014.
- 4 Keil G: [The history of plastic surgery (author's transl)]. *Laryngol Rhinol Otol*, 57(7): 581-91, 1978.
- 5 Tomba P, Viganò A, Ruggieri P, Gasbarrini A: Gaspare Tagliacozzi, pioneer of plastic surgery and the spread of his technique throughout Europe in “De Curtorum Chirurgia per Insitionem.” *Eur Rev Med Pharmacol Sci*, 18(4): 445-50, 2014.
- 6 Jefferies F: The Gentleman's Magazine, Volume 64, Part 2, Volumes 133 to 158, Volumes 357 to 394, Early English Newspapers, 1794.
- 7 Bardot J: Le traitement chirurgical des épithéliomes cutanés de la région centro faciale. Thèse, Marseille, 1984.
- 8 Divaris M: A propos de la reconstruction du nez. Analyse de 542 reconstructions. Thèse, Paris, 1989.
- 9 Spence RJ: Experience with novel uses of tissue expanders in burn reconstruction of the face and neck. *Ann Plast Surg*, 28(5): 453-64, 1992.
- 10 Frey M: The radial forearm flap as a pedicled flap for resurfacing a scarred nose. *Ann Plast Surg*, 32(2): 200-4, 1994.
- 11 Costa H, Cunha C, Guimarães I, Comba S et al.: Prefabricated flaps for the head and neck: a preliminary report. *Br J Plast Surg*, 46(3): 223-7, 1993.
- 12 Pribaz JJ, Fine N, Orgill DP: Flap prefabrication in the head and neck: a 10-year experience. *Plast Reconstr Surg*, 103(3): 808-20, 1999.
- 13 Nicolas J, Labbé D, Soubeyrand E, Guillou-Jamard M-R et al.: [Nasal reconstruction with a three-staged forehead flap: assessment of 16 cases]. *Rev Stomatol Chir Maxillofac*, 108(1): 21-8; discussion 28-30, 2007.
- 14 Converse JM, Wood-Smith D: Experiences with the forehead island flap with a subcutaneous pedicle. *Plast Reconstr Surg*, 31: 521-7, 1963.
- 15 Converse JM: Reconstruction of the nose by the scalping flap technique. *Surg Clin North Am*, 39(2): 335-65, 1959.
- 16 Jaramillo MJ, Stewart KJ, Kolhe PS: Phenytoin induced rhinophyma treated by excision and full thickness skin grafting. *Br J Plast Surg*, 53(6): 521-3, 2000.
- 17 Millard DR: Aesthetic reconstructive rhinoplasty. *Clin Plast Surg*, 8(2): 169-75, 1981.
- 18 Parkhouse N, Evans D: Reconstruction of the ala of the nose using a composite free flap from the pinna. *Br J Plast Surg*, 38(3): 306-13, 1985.
- 19 Millard DR: Hemirhinoplasty. *Plast Reconstr Surg*, 40(5): 440-5, 1967.
- 20 Millard DR: Reconstructive rhinoplasty for the lower half of a nose. *Plast Reconstr Surg*, 53(2): 133-9, 1974.
- 21 Hataya Y, Kosaka K, Yamazaki M, Asai S, Suzuki K: Reconstruction of burned nasal alae with vascular island skin flaps pedicled on the infraorbital vessels. *Burns*, 21(4): 313-5, 1995.
- 22 Shenaq SM, Dinh TA, Spira M: Nasal alar reconstruction with an ear helix free flap. *J Reconstr Microsurg*, 5(1): 63-7, 1989.
- 23 Burget GC: Aesthetic reconstruction of the tip of the nose. *Dermatol Surg*, 21(5): 419-29, 1995.
- 24 Barret JP, Herndon DN, McCauley RL: Use of previously burned skin as random cutaneous local flaps in pediatric burn reconstruction. *Burns*, 28(5): 500-2, 2002.
- 25 Chaput B, Lauwers F, Lopez R, Saboye J et al.: [Nose surgical anatomy in six aesthetic subunits]. *Ann Chir Plast Esthet*, 58(2): 132-45, 2013.